



# HIF-1 $\alpha$ and SOX2 expression in cervical squamous cell carcinoma

## Ekspresija HIF-1 $\alpha$ i SOX2 kod skvamoznih karcinoma grlića materice

Svetlana V. Milenković\*, Tatjana Terzić†, Boris Vraneš‡, Ivan Soldatović§

Clinical Center of Serbia, \*Pathology Department, †Clinic for Gynecology and Obstetrics, Belgrade, Serbia; University of Belgrade, Faculty of Medicine, ‡Institute of Pathology, §Institute for Medical Statistics and Informatics, Belgrade, Serbia

### Abstract

**Background/Aim.** Hypoxia is one of the major changes that occurs in the tumor microenvironment. It has been observed that there are pluripotent cancer cells in the cancer cell population that affect tumor growth and their resistance to therapy. The aim of this study was to examine the expression of hypoxia-inducible factor-1 alpha (HIF-1 $\alpha$ ), endogenous marker of hypoxia, and SOX2, marker of the pluripotent stem cells existing in the normal adult tissues, in the cervical squamous cell carcinoma (SCC). **Methods.** The study was conducted in 90 women with invasive cervical SCC, divided into two groups – 60 women in the Group A, with FIGO IB1 < 20 mm tumors (no metastases in the lymph nodes), and 30 women in the group B with tumors FIGO I–II (positive lymph nodes). The basic clinical parameters were determined by standard histopathological analysis, and the expression of HIF-1 $\alpha$  and SOX2 by immunohistochemical examination. **Results.** There was a significant difference between the groups A and B, in the expression of HIF-1 $\alpha$  ( $p = 0.024$ ), but not in the expression of SOX2 ( $p = 0.566$ ). Expression of HIF-1 $\alpha$  was significantly higher in the group with lymph node metastases and invasion of lymphovascular spaces ( $p < 0.001$ ) but not associated with tumor size ( $p = 0.291$ ) or lymphocytic stromal response ( $p = 0.940$ ). The tumor grade significantly influenced the expression of HIF-1 $\alpha$  ( $p = 0.013$ ). The expression of SOX2 did not significantly correlate with any of the established clinical tumor parameters. **Conclusion.** A significant difference in the expression of HIF-1  $\alpha$  between the group with and that without metastases in lymph nodes in invasive cervical SCC could distinguish HIF-1 $\alpha$  as a parameter of poor prognosis of the disease. The prognostic significance of SOX2 as well as a significant correlation between expression of HIF-1 $\alpha$  and SOX2 were not established.

**Key words:** uterine cervical neoplasms; neoplasm staging; prognosis; hypoxia; biomarkers.

### Apstrakt

**Uvod/Cilj.** Hipoksija je jedna od bitnih promena koja se dešava u mikrookolini tumora. Zapaženo je da u populaciji kancerskih ćelija postoje pluripotentne kancerske *stem* ćelije koje utiču na rast tumora i njihovu rezistenciju na terapiju. Cilj rada je bio da se kod bolesnica sa skvamoznim karcinomom (*squamous cell carcinoma* – SCC) grlića materice ispita ekspresija faktora 1 alfa indukovano hipoksijom (*hypoxia-inducible factor-1 alpha* – HIF-1 $\alpha$ ), endogenog markera hipoksije i SOX2, markera pluripotentnih stem ćelija koje postoje u normalnim tkivima odraslog čoveka. **Metode.** U ispitivanje je bilo uključeno 90 žena sa invazivnim SCC grlića materice podeljenih u dve grupe – 60 žena u grupi A, sa tumorima stadijuma FIGO IB1 < 20 mm (bez metastaza u limfnim nodusima) i 30 žena u grupi B, sa tumorima FIGO I–II (sa pozitivnim limfonodalnim statusom). Osnovni kliničkopatološki parametri su bili određeni standardnom patohistološkom analizom, a ekspresija HIF-1 $\alpha$  i SOX2 imunohistohemijskim ispitivanjem. **Rezultati.** Između grupa A i B utvrđena je značajna razlika u ekspresiji HIF-1 $\alpha$  ( $p = 0,024$ ), ali ne i u ekspresiji SOX2 ( $p = 0,566$ ). Ekspresija HIF-1 $\alpha$  bila je značajno viša u grupi sa limfonodalnim metastazama i invazijom limfovaskularnih prostora ( $p < 0,001$ ), ali nije bila povezana sa veličinom tumora ( $p = 0,291$ ) niti jačinom limfocitnog odgovora ( $p = 0,940$ ). Gradus tumora je značajno uticao na ekspresiju HIF-1 $\alpha$  ( $p = 0,013$ ). Ekspresija SOX2 nije značajno korelirala ni sa jednim utvrđenim kliničkopatološkim parametrom tumora. **Zaključak.** Značajna razlika u ekspresiji HIF-1 $\alpha$  između grupa sa i bez metastaza u limfnim nodusima kod invazivnog SCC grlića materice mogla bi izdvojiti HIF-1 $\alpha$  kao parametar loše prognoze bolesti. Nije utvrđen prognostički značaj SOX2, niti značajna uzajamna korelacija ekspresije HIF-1 $\alpha$  i SOX2.

**Ključne reči:** materica, neoplazme; neoplazme, određivanje stadijuma; prognoza; hipoksija; biološki pokazatelji.

## Introduction

Cervical cancer is the third most common malignant tumor of women in the world, and Serbia is ranked fourth in Europe<sup>1</sup>. The most common histological type of invasive cervical cancer according to the WHO classification is squamous cell carcinoma (SCC) with a frequency of 70%–80%, while the frequency of other types is much lower<sup>2</sup>. The therapeutic procedure is determined according to the clinical the International Federation of Obstetrics and Gynecology (FIGO) stage of the tumor disease. There are four FIGO stages, FIGO I–IV, which are determined regardless of the histological type of tumor. Small invasive cervical cancer is a FIGO IA, and FIGO IB1 indicates tumor smaller than 20 mm. Standard treatment for the stages FIGO IA1 and FIGO IA2, FIGO IB1 and IB2, as well as FIGO IIA is surgical, while primary treatment for the stages from FIGO IIB to FIGO IV is chemoradiotherapy.

In the last decades numerous attempts have been made to determine the prognostic factors that influence the transformation of preinvasive stage to malignant one, the tumor spreading process, and its metastatic potential, by determining the tumor immunophenotype and its environment. It is considered that one of the factors of the malignant transformation of the cell are changes in its microenvironment, which include, among other things, damage of blood vessels, the formation of hypoxic focus and the maintenance of hypoxia by the activation of signal molecules, such as hypoxia-inducible factor 1-alpha (HIF-1 $\alpha$ ). HIF-1 $\alpha$  is part of the transcriptional complex involved in the regulation of many aspects of tumor biology. Increased activation of HIF-1 $\alpha$  or hypoxia causes the transition from oxidative to glycolytic metabolism and leads to increased expression of angiogenesis markers [vascular endothelial growth factor (VEGF)] and of numerous metabolic markers, such as: glucose transporter 1 (GLUT-1), c-met and carbonic anhydrase 9 (CA9), which in recent years have been the subject of intensive research, not only as prognostic parameters of the disease, but also for potentially targeted therapy<sup>3</sup>.

Karsten and Goletz<sup>4</sup> found that one of the important reasons for the difference between cancer and normal stem cells is the effect of microenvironment, where hypoxia plays an important role. SOX2 was initially known as a protein that maintains stem cells in the mature tissue of an adult (including brain tissue), and then it has been confirmed that it is one of the leading transcriptional proteins that affect the induction of pluripotent stem cells<sup>5</sup>. Excessive expression and genetic amplification of SOX2 are, however, associated with the formation of SCC in various tissues<sup>6</sup>. The assumption is that enhanced SOX2 expression affects the proliferation of cancer stem cells and provides worse prognosis<sup>7</sup>.

The aim of this study was to determine the expression of HIF-1 $\alpha$  and SOX2 and to compare it between FIGO IB1 and FIGO I–II stages. In addition, we wanted to determine whether there was a relationship between the level of expression of these two markers, as well as their relationship with clinicopathological parameters: FIGO stage of tumor disease,

tumor size, tumor grade, lymphovascular invasion (LVSI), and metastases in the lymph nodes.

## Methods

The study included 90 patients with a histopathologically confirmed diagnosis of cervical SCC. They were surgically treated at the Gynecology Clinic of the Clinical Center of Serbia in Belgrade, Serbia. All women had radical hysterectomy with lymphadenectomy and on the basis of a definitive finding, the entire group was divided into two groups: the group A – small invasive carcinoma of the stage FIGO IB1 < 20 mm (60 patient), and the group B – all cases of cervical SCC in which metastases existed in lymph nodes (30 patients).

From the group A, with small invasive carcinoma, we excluded: patients with microinvasive carcinoma of the stage FIGO IA1 and FIGO IA2, patients with stage FIGO IB1 in which the tumor was greater than 20 mm, patients of the stage FIGO IB2 and more.

The group B included patients with positive lymph nodes, regardless of the FIGO stage, so in this group there were women in the stages of FIGO IA1, FIGO IB1 (irrespective of the size of the tumor), FIGO IB2, FIGO IIA and FIGO IIB. The number of positive lymph nodes was not important for inclusion in this group.

The common criteria for both groups were: women who previously had not any other type of oncological treatment of their illness, and those without other malignancies, including gynecological malignancies outside the cervix.

Biopsy material in paraffin blocks was processed in the laboratory of the Department of Pathology of the Clinical Center of Serbia in Belgrade. The obtained samples of cervical tumor tissue, fixed in 10% neutral buffered formalin and embedded into paraffin blocks were analyzed on standard hematoxylin-eosin colored cross-sections of 4  $\mu$ m in order to establish a pathohistological diagnosis. The study included cases of squamous differentiation, whereas adenocarcinomas, adenosquamous carcinoma and other rare types of tumors were excluded. The pathological report determined the size of the tumor, degree of differentiation, nuclear grade, lymphovascular invasion, lymphocytic response, parametrial and vaginal wall involvement, number of lymph nodes taken out and number of positive lymph nodes.

From the obtained preparations, the most homogeneous field for further processing is selected using the tissue microarray (TMA) method. From the selected paraffin blocks, from the field of the most homogeneous tumor tissue, 2 tissue cylinders (per patient) were taken, using a 2 mm puncture needle, and then inserted into a new paraffin block (TMA block), where a 60-cylinder series was placed. Each TMA block was cut at a thickness of 4  $\mu$ m, and after deparaffinization and heat treatment an immunohistochemical (IHC) analysis was performed.

### *Immunohistochemical analysis*

Immunohistochemistry was performed on archived formalin-fixed, paraffin-embedded tissue, using a manual

method for HIF-1 $\alpha$  antibody (EP1215Y, Abcam) at 1 : 100 dilution. Pretreatment antigen retrieval by microwave heating in 10 mM citrate buffer pH 6 was performed according to the manufacturer's directions and current laboratory protocol, applying avidin-biotin complex method (UltraVision™ Detection System, Termoscientific) using 3,3'-diaminobenzidine (DAB) as chromogen. Nuclear and cytoplasmic staining were analysed. The positive control was ovarian carcinoma.

HIC stain for SOX 2 antibody (SP76, Ventana) was done automatically (Leica Bond), according to the manufacturer's directions and resulted in nuclear staining of variable intensity in the positive cases.

Expression was quantitatively analyzed by determining the intensity of coloring and the percentage of positive tumor cells. The quantitative scale for the intensity and percentage of colored tumor cells is categorized into 4 and 5 classes, respectively in the following way: coloring intensity – 0 (colorless), 1+ (poor), 2+ (medium), 3+ (strong), and percentage of positive carcinoma cells in relation to the total number of tumor cells – 0 (< 5%), 1+ (6%–25%), 2+ (26%–50%), 3+ (51%–75%), 4+ (> 75%). The final IHC score is calculated as a combination of intensity and percentage scores (range 0–12). The values of < 4 indicated a weak positivity, 5–8 moderate, and 9–12 a strong positivity of expression.

#### Statistical analysis

Results are presented as count (%) or mean  $\pm$  standard deviation depending on data type. Groups are compared using *t* test, ANOVA,  $\chi^2$  test (Pearson and Cochran-Armitage test), Kruskal-Wallis and Mann-Whitney *U* test. To assess correlation between variables Spearman's correlation was used. All *p* values less than 0.05 were considered significant. All data was analyzed using SPSS 20.0 (IBM Corp. Released 2011. IBM SPSS Statistics for Windows, Version 20.0. Armonk, NY: IBM Corp.).

#### Results

In the group A, 60 cases of small invasive tumors were analyzed. The average age of women was 45.2 years, the oldest patient was 53 years old and the youngest one 37, with a standard deviation rate of  $\pm$  10.1 years. In the group B, the youngest woman had 28 and oldest 71 year, with an average of  $51.9 \pm 11.8$  years.

In the group A all women were clinical FIGO IB1 stage, with the largest dimension of a tumor of up to 20 mm. In the group B, all women had metastatic disease in lymph nodes, but their FIGO stages were different: 2/30 patients were at the stage FIGO IA1, 10/30 were at the stage FIGO IB1 (all > 20 mm), 9/30 women had FIGO IB2 stages (tumor > 40 mm), 4 women had infiltration of the vagina – FIGO IIA stage, and 5 women had a parametrial infiltration – FIGO IIB stage. For both groups, the total tumor volume was calculated.

All prognostic parameters of the tumor were determined by histopathological analysis. The average tumor volume in the group A was 1,420 (625–2,405) mm<sup>3</sup>, and in the group B 19,775 (8,000–40,500) mm<sup>3</sup>. For the degree of differentiation, the Broders classification was used. The group A had the highest number of moderately differentiated carcinomas (G2) – 66.7%, and much less well differentiated (G1) 3.3% and poorly differentiated cases (G3) 31.3% which makes 63.5% of G2, 100% of G1 and 72% of G3 tumors, of the total number of cases in both groups. In the group B there were no well-differentiated cases; the G2 tumor was present in 23/30 (76.7%) cases and G3 in 7/30 (23.3%) cases, corresponding to 36.5% of G2 and 28% of G3 SCCs of a total of 90 analyzed in the groups A and B.

Lymphovascular invasion was not present in 40 cases in the group A, while 33.3% of patients in this group had an invasion of blood and/or lymph vessels.

After standard analysis and determination of clinicopathological parameters, an IHC analysis of HIF-1 $\alpha$  and SOX2 was performed. Results for HIF-1 $\alpha$  were classified into 3 categories, where the first category comprised cases with a negative and weak positive reaction, in the second category there were cases of moderate positivity, and in the third category there were tumors that showed strong expression. The SOX2 expression was also divided into three groups: cases with a negative reaction, cases with weak positive expression, while cases of moderate and severe expression are classified in the same group. Due to statistical processing, the number of categories was adjusted to the number of samples in both groups.

In the group A, only one (1.7%) case showed a negative reaction to HIF-1 $\alpha$ , 20 (33.3%) cases were weak positive, 14 (23.3%) were strongly positive, and the most showed moderately positive reactions – 25/60 (41.7%) cases. In the group B, 19/30 cases had a negative or weak, 5/30 moderate and 6/30 strong reaction to HIF-1 $\alpha$ . The obtained results showed a statistically significant difference between the group A and the group B (*p* = 0.024) in the expression of hypoxia markers. However, in the expression of SOX2, no significant difference was found between these groups (*p* = 0.566). Only 11/60 tumors in the group A and 6/30 of SCC in the group B had moderate or strong positivity, while the majority of cases were either negative or poorly positive (Table 1).

We analyzed the correlation between the expression of HIF-1 $\alpha$  and the defined clinical-pathological parameters and found that it existed in relation to a tumor grade (*p* = 0.013), lymph node metastases and a LVSI (*p* = 0.006), but it was not expressed in relation to a tumor size or volume (*p* = 0.291) nor a strength of the inflammatory stromal response (*p* = 0.940) (Table 2).

The expression of SOX2 was analyzed in relation to clinicopathological parameters. No statistically significant association was found in any category: in relation to a tumor grade (*p* = 0.331), invasion of vascular spaces (*p* = 0.645), and a lymphocytic stromal response (*p* = 0.916) (Table 3).

There was no significant association in the expression of HIF-1 $\alpha$  and SOX2 ( $\rho$  = 0.132; *p* = 0.215) (Figures 1 and 2).

**Table 1**  
**Clinicopathological characteristics and levels of expression of HIF-1 $\alpha$  and SOX2 in patients with cervical squamous cell carcinoma**

Variable	Metastases		<i>p</i> value
	no	yes	
Age (years), mean $\pm$ SD	45.2 $\pm$ 10.1	51.9 $\pm$ 11.8	0.006 <sup>a</sup>
Tumor dimensions (mm), mean $\pm$ SD			
length (mm)	14.3 $\pm$ 4.6	29.8 $\pm$ 12.0	< 0.001 <sup>b</sup>
width (mm)	11.9 $\pm$ 4.2	28.8 $\pm$ 12.7	< 0.001 <sup>b</sup>
depth (mm)	8.6 $\pm$ 4.2	22.1 $\pm$ 9.7	< 0.001 <sup>b</sup>
volume (mm <sup>3</sup> )	1,420 (625–2,405)	19,775 (8,000–40,500)	< 0.001 <sup>b</sup>
LVSI, n (%)			
no	40 (100)	0	
lymph or vascular	5 (74.4)	2 (28.6)	< 0.001 <sup>c</sup>
both lymph and vascular	15 (34.9)	28 (65.1)	
Tumor grade, n (%)			
1	2 (100)	0	
2	40 (63.5)	23 (36.5)	0.821 <sup>d</sup>
3	18 (72.0)	7 (28.0)	
Stage, n (%)			
IB1 < 20 mm	60 (92.3)	5 (7.7)	< 0.001 <sup>c</sup>
other	0	25 (100)	
HIF-1 $\alpha$ , n (%)			
no/weak	21 (52.5)	19 (47.5)	
moderate	25 (83.3)	5 (16.7)	0.024 <sup>c</sup>
strong	14 (70)	6 (30)	
SOX2, n (%)			
no	33 (70.2)	14 (29.8)	
weak	16 (61.5)	10 (38.5)	0.566 <sup>d</sup>
moderate/strong	11 (64.7)	6 (35.3)	
Lymphocytic stromal response, n (%)			
weak	19 (61.3)	12 (38.7)	
moderate	16 (59.3)	11 (40.7)	0.041 <sup>d</sup>
strong	25 (86.2)	4 (13.8)	

LVSI – lymphovascular invasion; HIF-1 $\alpha$  – hypoxia-inducible factor 1-alpha; SD – standard deviation.  
<sup>a</sup>*t*-test; <sup>b</sup>Mann-Whitney *U* test; <sup>c</sup>Pearson  $\chi^2$  test; <sup>d</sup> $\chi^2$  test for trend (Cochrane-Armitage test).

**Table 2**  
**Expression of HIF-1 $\alpha$  in relation to clinicopathological characteristics in patients with cervical squamous cell carcinoma**

Variable	HIF-1 $\alpha$			<i>p</i> value
	no/weak	moderate	strong	
Age (years), mean $\pm$ SD	49.6 $\pm$ 10.7	46.1 $\pm$ 10.8	45.2 $\pm$ 12.1	0.253 <sup>a</sup>
Tumor dimensions, mean $\pm$ SD				
length (mm)	22.5 $\pm$ 12.4	16.8 $\pm$ 9.2	17.3 $\pm$ 7.5	0.095 <sup>b</sup>
width (mm)	19.2 $\pm$ 13.3	16.0 $\pm$ 9.3	16.6 $\pm$ 9.9	0.752 <sup>b</sup>
depth (mm)	14.7 $\pm$ 10.1	10.3 $\pm$ 6.1	13.3 $\pm$ 10.1	0.242 <sup>b</sup>
volume (mm <sup>3</sup> )	2,630 (1,125–22,775)	1,590 (750–3,780)	2,625 (960–5700)	0.291 <sup>b</sup>
LVSI, n (%)				
no	13 (32.5)	20 (66.7)	7 (35)	
lymph or vascular	2 (5)	1 (3.3)	4 (20)	0.006 <sup>c</sup>
both lymph and vascular	25 (62.5)	9 (30)	9 (45)	
Grade, n (%)				
1	1 (2.5)	1 (3.3)	0	
2	32 (80)	21 (70)	10 (50)	0.013 <sup>d</sup>
3	7 (17.5)	8 (26.7)	10 (50)	
Lymphocytic response, n (%)				
weak	16 (41)	8 (27.6)	7 (36.8)	
moderate	10 (25.6)	9 (31)	8 (42.1)	0.940 <sup>d</sup>
strong	13 (33.3)	12 (41.4)	4 (21.1)	

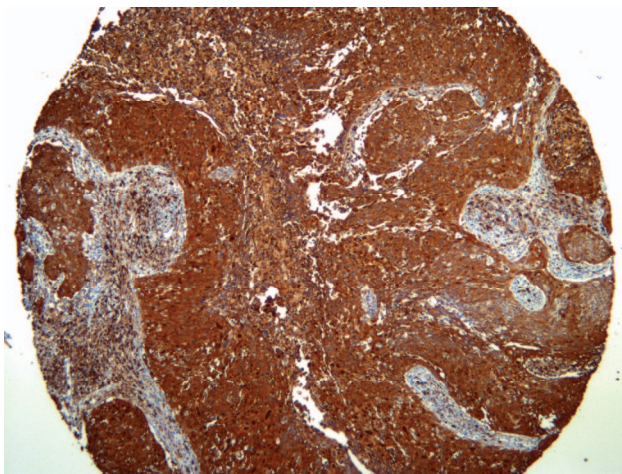
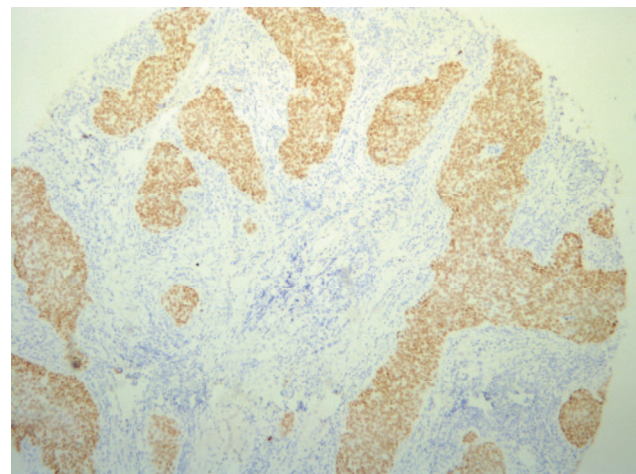
For the abbreviations see under Table 1.

<sup>a</sup>ANOVA; <sup>b</sup>Kruskal-Wallis test; <sup>c</sup>Pearson  $\chi^2$  test; <sup>d</sup> $\chi^2$ -test for trend (Cochrane-Armitage test).

**Table 3****Correlation between the expression of SOX2 and clinicopathological parameters in patients with cervical squamous cell carcinoma**

Variable	SOX2			p value
	no	weak	moderate/strong	
Age (years), mean ± SD	48.5 ± 12.3	44.3 ± 9.3	49.5 ± 9.7	0.229 <sup>a</sup>
Tumor dimensions, mean ± SD				
length (mm)	19.7 ± 10.5	17.6 ± 10.9	21.8 ± 11.1	0.534 <sup>b</sup>
width (mm)	18.3 ± 11.5	16.6 ± 13.5	17.1 ± 6.7	0.423 <sup>b</sup>
depth (mm)	13.5 ± 9.7	11.9 ± 9.2	12.5 ± 7.4	0.910 <sup>b</sup>
volume (mm <sup>3</sup> )	2,250 (1,000–8,000)	1,710 (1,050–3,780)	3,000 (960–11,500)	0.726 <sup>b</sup>
LVSI, n (%)				
no	20 (42.6)	13 (50)	7 (41.2)	0.645 <sup>c</sup>
lymph or vascular	2 (4.3)	3 (11.5)	2 (11.8)	
both lymph and vascular	25 (53.2)	10 (38.5)	8 (47.1)	
Grade, n (%)				
1	2 (4.3)	0	0	0.331 <sup>d</sup>
2	35 (74.5)	15 (57.7)	13 (76.5)	
3	10 (21.3)	11 (42.3)	4 (23.5)	
Lymphocytic response, n (%)				
weak	16 (35.6)	7 (28.0)	8 (47.1)	0.916 <sup>d</sup>
moderate	15 (33.3)	9 (36)	3 (17.6)	
strong	14 (31.1)	9 (36)	6 (35.3)	

For the abbreviations see under Table 1.

<sup>a</sup>ANOVA; <sup>b</sup>Kruskal-Wallis test; <sup>c</sup>Pearson  $\chi^2$  test; <sup>d</sup> $\chi^2$ -test for trend (Cochrane-Armitage test).**Fig. 1 – Immunohistochemical expression of hypoxia-inducible factor-1 alpha (×40).****Fig. 2 – Immunohistochemical expression of SOX2 (×100).**

### Discussion

Screening programs in highly developed countries record mainly cases of premalignant changes in the cervix. However, for the rest of the world, invasive cervical cancer is still one of the leading causes of morbidity and mortality in the female population. In Serbia, this malignant tumor is at the 3rd place at the rate of mortality, because a large number of patients appear in advanced stages of the disease, when additional radiation or combined chemoradiotherapy is required.

One of the main reasons for the weaker success of additional therapy is hypoxia that occurs in solid tumors, and many studies are focused on enhancing oxygenation in tumors. HIF-1 as a parameter of hypoxic conditions in a changed microenvironment has been the target of numerous trials aimed at finding targeted therapy, during the last decade. It has been confirmed that HIF-1 is composed of two domains: alpha and beta, and HIF-1 $\alpha$  consists of three different components: HIF-1 $\alpha$ , HIF-2 $\alpha$  and the least known HIF-3 $\alpha$ .

Most of the studies have been carried out to estimate the expression of HIF-1 $\alpha$  and its effects on various tumor characteristics, such as neoangiogenesis, metabolic reprogramming, genetic instability, cancer stem cells proliferation, invasiveness and metastasis, immune response of the host, survival and resistance to applied therapies. It has been shown that enhanced HIF-1 expression is a parameter of poor prognosis for many malignant tumors, both in the cases of the primary process and in metastatic disease.

Numerous, early trials were performed on tumors of the breast and ovaries, and then extended to other gynecological tumors, and tumors of other localities, irrespective of the type of differentiation. In most of those papers, the influence of HIF-1 $\alpha$  marker is observed in correlation with the vascular endothelial growth factor marker of neoangiogenesis. The summarized results of the study by Jin et al.<sup>8</sup>, observing the prognostic effect of HIF-1 $\alpha$  marker expression on tumors of gynecological origin, show a significant but still insufficiently clear role of this hypoxia marker. The meta-analysis included 59 different studies with the conclusion that HIF-1 $\alpha$  was associated with FIGO stage, tumor grade, lymph node metastases, 5-year survival and recurrence rate. The results were as follows: expression in the stage III–IV or in the presence of metastases in lymph nodes was significantly higher than in the stage I–II with or without metastases in lymph nodes, respectively ( $p < 0.00001$ ,  $p < 0.0001$ , respectively); compared to tumor grade (gradus 3 vs. gradus 1:  $p < 0.00001$ ; gradus 3 vs. gradus 2:  $p = 0.002$ ; gradus 2 vs. gradus 1:  $p < 0.00001$   $p < 0.00001$ ), 5-year survival without disease ( $p = 0.001$ ) and 5-year survival ( $p < 0.000$ ).

However, the results regarding the relationship of HIF-1 $\alpha$  and cervical carcinoma are heterogeneous and partly contradictory. In the study of Huang et al.<sup>9</sup> it has been stated that the excessive expression of HIF-1 $\alpha$  in invasive carcinoma is present in 94.6% of subjects, with a significant association with FIGO stage ( $p = 0.024$ ) and tumor size ( $p = 0.003$ ), which our research did not show.

In the work of Kim et al.<sup>10</sup>, HIF-1 $\alpha$  strong positivity was present in 39.7% of analyzed cervical cancers and correlated significantly with FIGO stage ( $p < 0.001$ ) and lymph node positivity ( $p < 0.001$ ). Our findings are similar. The increased activity of HIF-1 $\alpha$  causes a decrease in the activity of E cadherin, an adhesive cellular molecule that suppresses the invasion and metastases by maintaining cell integrity. However, there was no significant association of expression of HIF-1 $\alpha$  with tumor size ( $p = 0.210$ ) and invasion of blood and lymph vessels ( $p = 0.725$ ).

In our study, 50 cases of a total of 90, showed moderate and strong positivity for HIF-1 $\alpha$ . According to Iwasaki et al.<sup>11</sup>, 28 cases of 54 were positive for HIF-1 $\alpha$ , with significant association with FIGO stage ( $p = 0.0349$ ) and tumor type (more significant expression in adenocarcinomas compared to squamous) but no association with lymph node metastases ( $p = 0.5615$ ), LVSI ( $p = 0.2350$ ), or tumor size ( $p = 0.5826$ ). Our results obviously partially coincide with the already published results of other authors, but there are some disagreements. It is interesting that each study com-

pared to the previous one had deviations in significance, at least in some histopathological parameters.

There are several ways to explain differences in the obtained results. The antibodies used in the IHC analysis in studies are by different manufacturers and this is considered to be one of the explanations why controversial results were obtained<sup>12</sup>. The degree of cytoplasmic and nuclear positivity also varies, which affects the assessment of the strength of expression. Some authors include only nuclear positivity, while in other papers both nuclear and cytoplasmic staining are considered in estimating positive reaction<sup>10</sup>. An important reason is the interobserver difference in the interpretation of the results, considering the fact that automated digital analysis of expression is not used in most cases<sup>13</sup>.

In recent studies that indicate an increased expression of HIF-1 $\alpha$  as a prognostic parameter for endometrial carcinoma, there are also some other explanations for the observed differences. There is no established cut off value that defines excessive expression of HIF-1 $\alpha$ , and no clearly defined field in which expression is determined. In most papers related to cervical carcinomas, the IHC reaction is determined only in the carcinoma islands, while in the case of endometrial carcinoma it is the case of the inverse influence of stromal and carcinogenic positivity of HIF-1 $\alpha$  – high stromal and low carcinoma HIF-1 $\alpha$  positivity is a parameter of poor prognosis<sup>14</sup>.

In the paper of Seeber et al.<sup>15</sup>, correlation between necrosis and HIF-1 $\alpha$  expression is also observed in endometrioid carcinoma, with the emphasis only on nuclear positivity in cancer cells in three different aspects: perinecrotic positivity, diffuse positivity or mixed (combinations of the preceding two), which indicates the difference in interpretation and the discordance in determining the positivity of the hypoxia markers. We should not neglect the fact that the general condition of a patient can also affect variations in the values of HIF-1 $\alpha$ , e.g. hyperglycemia or hemoglobinemia<sup>16</sup>.

Interestingly, in some studies it has been shown that there is no significant difference between the increased expression of HIF-1 $\alpha$  in high grade squamous intraepithelial lesions and in invasive carcinoma, which is considered to be evidence that this endogenous metabolic marker is involved in early stages of tumor development, associating it with highly oncogenic human papilloma virus (HPV)<sup>17,18</sup>. The HPV E6 oncoprotein, the p53 tumor suppressor gene inactivator, increases the stability of HIF-1 $\alpha$  and enhances the expression of HIF-1 $\alpha$ -dependent VEGF in hypoxic conditions, so it is believed that HIF-1 $\alpha$  is not only a prognostic parameter but also plays an important role in progression from pre-invasive lesion to invasive disease.

Much less is known about the association of SOX2 and the tumor process. The research was directed to finding the link between SOX2 and cancer stem cells, with the conclusion that its overexpression and genetic amplification were associated with the formation of SCC in various tissues, including the lungs and esophagus<sup>19</sup>. In the review paper of Weina and Utikal<sup>20</sup>, the obtained results are summarized, and through various mechanisms, by determining the genetic amplification, it is concluded that SOX2 can be a prognostic

marker, a metastatic indicator, a biomarker, or a potential targeted therapy for certain types of tumors such as pancreatic, esophageal SCC, carcinomas of lungs and oral regions, and, in particular, in tumors of neurogenic origin.

However, for cervical cancer, gene amplification is listed as unknown, and that is the mechanism through which it works. Ji and Zheng<sup>21</sup> in their work state that the SOX2 nuclear expression, as an IHC reaction, was significantly higher ( $p = 0.05$ ) in SCC cells than in the normal epithelium<sup>21</sup>, with the conclusion that the expression is much higher as the tumor was less differentiated, but for all other clinical pathological parameters there was no significant difference.

Our results are concordant with results of the research of Yang et al.<sup>22</sup>, in which, unlike in the study by Ji and Zheng<sup>21</sup>, there was no statistically significant difference in the degree of tumor differentiation. The digital software system analyzed the cytoplasmic positive reaction of SOX2 in the carcinoma cells, and the obtained expression did not correlate with clinicoathological parameters – FIGO stage of tumor disease ( $p = 0.519$ ), histological tumor grade (0.594), tumor size ( $p = 0.493$ ), vascular invasion ( $p = 0.592$ ) and lymph node metastases ( $p = 0.181$ ).

In their study, Kim et al.<sup>23</sup> showed a somewhat different result, revealing a significant difference in the tumor size category ( $p = 0.015$ ), but not in FIGO stages ( $p = 0.519$ ), the degree of tumor differentiation, lymphovascular invasion, or lymph node metastases ( $p = 0.879$ ), which is in accordance with results of Yang et al.<sup>22</sup>, as well as our results.

Interesting observations are given in the paper by Stewart and Crook<sup>24</sup>. They noted that most of the squamous cells in squamous intraepithelial lesions were SOX2 positive, and that most of the cancer cells in the FIGO IA1 group (early invasive tumors) were completely negative or weakly positive, and that corresponds with our results. The authors suggest that the explanation might be in the disorder of SOX2 regulation during the initial stages of the invasive processes, or that the progression of cervical SCC may include cyclical changes in the activity of SOX2.

In our study there was no link between HIF-1 $\alpha$  and SOX2 expression in the two investigated groups, i.e. no sig-

nificant coexpression of these two markers was found. There is a small number of studies determining their connection. Miyazawa et al.<sup>25</sup> showed a significant relationship between expression of HIF-1 $\alpha$  and two other stem cells markers, NANOG and OCT4, that coexpress with SOX2, using prostate carcinoma samples. Mathieu et al.<sup>26</sup> link hypoxia or its endogenous HIF marker with increased transcription of stem cell markers: NANOG; SOX2, OCT4 (and others) within eleven cancers including cervical cancer. However, most papers are not based on the application of IHC methods, but on molecular-genetic analyzes, so perhaps the difference in the obtained results can be explained by differences in the specificity and sensitivity of the applied methods. Keith et al.<sup>27</sup> conclude that HIF-1 influences glucose metabolism disorder, while HIF-2 is included in OCT4-regulated stem cell pluripotency (OCT4 is coexpressed with SOX2). In our research we used HIF-1 $\alpha$ , not HIF-2 $\alpha$ , so maybe this is a part of the explanation why we did not get the link between the HIF-1 $\alpha$  and SOX2 markers.

### Conclusion

The importance of SOX2 as a prognostic parameter for cervical SCC, as well as the correlation of the HIF-1 $\alpha$  and SOX2 expression, has not been established. However, the significant difference between small invasive carcinomas without lymph node metastases and invasive carcinomas with lymph nodes metastases (regardless of FIGO stage) in expression of HIF-1 $\alpha$  confirms the role of hypoxia in the tumor microenvironment, in the process of invasion and metastasis. This is defining HIF-1 $\alpha$  as a poor prognostic parameter. The increase in oxygenation in the tumor microenvironment and/or inhibition of this marker activity could be a basis for targeted therapy. So far, certain inhibitors of HIF-1 $\alpha$  were used in the treatment of advanced breast carcinoma and renal cell carcinoma, so it is possible to expect their usage in advanced stages of cervical cancers, as well. However, before treatment and for determination of HIF-1 $\alpha$  expression, it is important to work out a standardization of IHC and/or other molecular methods with a goal of results validity estimation.

### R E F E R E N C E S

1. Ferlay J, Soerjomataram I, Ervik M, Dikshit R, Eser S, Mathers C, et al. GLOBOCAN 2012 v1.0, Cancer Incidence and Mortality Worldwide: IARC CancerBase No. 11 [Internet]. Lyon, France: International Agency for Research on Cancer; 2013.
2. Kurman RJ, Carcangiu ML, Herrington CS, Young RH. WHO Classification of Tumours of Female Reproductive Organs. 4th ed. Lyon: IARC Press; 2015.
3. Ziello JE, Jovin IS, Huang Y. Hypoxia-Inducible Factor (HIF)-1 regulatory pathway and its potential for therapeutic intervention in malignancy and ischemia. *Yale J Biol Med* 2007; 80(2): 51–60.
4. Karsten U, Goletz S. What makes cancer stem cell markers different? *Springerplus* 2013; 2(1): 301.
5. Zhang S, Cui W. Sox2, a key factor in the regulation of pluripotency and neural differentiation. *World J Stem Cells* 2014; 6(3): 305–11.
6. Ferone G, Song J, Sutherland K, Bhaskaran R, Monkborst K, Lambouij J, et al. SOX2 Is the Determining oncogenic switch in promoting lung squamous cell carcinoma from different cells of origin. *Cancer Cell* 2016; 30(4): 519–32.
7. Jian Z, Strait A, Jimeno A, Wang X. Cancer stem cells in squamous cell carcinoma. *J Invest Dermatol* 2017; 137(1): 31–7.
8. Jin Y, Wang H, Ma X, Liang X, Liu X, Wang Y. Clinicopathological characteristics of gynecological cancer associated with hypoxia-inducible factor 1 $\alpha$  expression: a meta-analysis including 6,612 subjects. *PLoS One* 2015; 10(5): e0127229.
9. Huang M, Chen Q, Xiao J, Yao T, Bian L, Liu C, et al. Overexpression of hypoxia-inducible factor-1 $\alpha$  is a predictor of poor prognosis in cervical cancer: a clinicopathologic study and a meta-analysis. *Int J Gynecol Cancer* 2014; 24(6): 1054–64.
10. Kim B, Cho H, Chung J, Conway C, Yllya K, Kim J, et al. Prognostic assessment of hypoxia and metabolic markers in cervical

- cancer using automated digital image analysis of immunohistochemistry. *J Transl Med* 2013; 11(1): 185.
11. *Inasaki K, Yabushita H, Ueno T, Wakatsuki A.* Role of hypoxia-inducible factor-1 $\alpha$ , carbonic anhydrase-IX, glucose transporter-1 and vascular endothelial growth factor associated with lymph node metastasis and recurrence in patients with locally advanced cervical cancer. *Oncol Lett* 2015; 10(4): 1970–8.
  12. *Daponte A, Ioannou M, Mylonis I, Simos G, Minas M, Messinis IE,* et al. Prognostic significance of Hypoxia-Inducible Factor 1 alpha(HIF-1alpha) expression in serous ovarian cancer: an immunohistochemical study. *BMC Cancer* 2008; 8: 335.
  13. *Hewitt SM, Lewis FA, Cao Y, Conrad RC, Cronin M, Goralski DJ,* et al. Tissue handling and specimen preparation in surgical pathology: issues concerning the recovery of nucleic acids from formalin-fixed, paraffin-embedded tissue. *Arch Pathol Lab Med* 2008; 132(12): 1929–35.
  14. *Berg A, Fasmer KE, Mauland KK, Ytre-Hauge S, Hovik EA, Husby JA,* et al. Tissue and imaging biomarkers for hypoxia predict poor outcome in endometrial cancer. *Oncotarget* 2016; 7(43): 69844–56.
  15. *Seeber LM, Horré N, van der Groep P, van der Wall E, Verbeijen RH, van Diest PJ.* Necrosis related HIF-1 $\alpha$  expression predicts prognosis in patients with endometrioid endometrial carcinoma. *BMC Cancer* 2010; 10(1): 307.
  16. *Koukourakis MI, Giatromanolaki A, Polychronidis A, Simopoulos C, Gatter KC, Harris AL,* et al. Endogenous markers of hypoxia/anaerobic metabolism and anemia in primary colorectal cancer. *Cancer Sci* 2006; 97(7): 582–8.
  17. *Tang X, Zhang Q, Nishitani J, Brown J, Shi S, Le AD.* Overexpression of human papillomavirus type 16 oncoproteins enhances hypoxia-inducible factor 1 alpha protein accumulation and vascular endothelial growth factor expression in human cervical carcinoma cells. *Clin Cancer Res* 2007; 13(9): 2568–76.
  18. *Liu F, Lin B, Liu X, Zhang W, Zhang E, Hu L,* et al. ERK Signaling Pathway Is Involved in HPV-16 E6 but not E7 Onco-protein-Induced HIF-1 $\alpha$  Protein Accumulation in NSCLC Cells. *Oncol Res* 2016; 23(3): 109–18.
  19. *Liu K, Lin B, Zhao M, Yang X, Chen M, Gao A,* et al. The multiple roles for Sox2 in stem cell maintenance and tumorigenesis. *Cell Signal* 2013; 25(5): 1264–71.
  20. *Weina K, Utikal J.* SOX2 and cancer: current research and its implications in the clinic. *Clin Transl Med* 2014; 3(1): 19.
  21. *Ji J, Zheng P.* Expression of Sox2 in human cervical carcinogenesis. *Hum Pathol* 2010; 41(10): 1438–47.
  22. *Yang Z, Pan X, Gao A, Zhu W.* Expression of Sox2 in cervical squamous cell carcinoma. *J BUON* 2014; 19(1): 203–6.
  23. *Kim BW, Cho H, Choi CH, Ylaya K, Chung J, Kim J,* et al. Clinical significance of OCT4 and SOX2 protein expression in cervical cancer. *BMC Cancer* 2015; 15(1): 1015.
  24. *Stewart CJ, Crook M.* SOX2 Expression in Cervical Intraepithelial Neoplasia Grade 3 (CIN3) and Superficially Invasive (Stage IA1) Squamous Carcinoma of the Cervix. *Int J Gynecol Pathol* 2016; 35(6): 566–73.
  25. *Miyazawa K, Tanaka T, Nakai D, Morita N, Suzuki K.* Immunohistochemical expression of four different stem cell markers in prostate cancer: High expression of NANOG in conjunction with hypoxia-inducible factor-1 $\alpha$  expression is involved in prostate epithelial malignancy. *Oncol Lett* 2014; 8(3): 985–92.
  26. *Mathieu J, Zhang Z, Zhou W, Wang AJ, Heddleston JM, Pinna CM,* et al. HIF induces human embryonic stem cell markers in cancer cells. *Cancer Res* 2011; 71(13): 4640–52.
  27. *Keith B, Johnson RS, Simon MC.* HIF1 $\alpha$  and HIF2 $\alpha$ : sibling rivalry in hypoxic tumour growth and progression. *Nat Rev Cancer* 2012; 12(1): 9–22.

Received on December 13, 2017.

Revised on February 28, 2018.

Accepted on March 7, 2018.

Online First March, 2018.